

# The Bhopal gas tragedy: An environmental disaster

S. Sriramachari

*The multi-disciplinary study of histopathology and toxicology of Bhopal gas tragedy resolved several issues. First, the progression of severe pulmonary oedema to chronic fibrosis was confirmed experimentally, following a single exposure to MIC. Analysis of the residue in Tank 610 revealed over 21 chemicals. Apart from MIC and HCN, some of them were tracked down to the blood and viscera of dead and living 'exposees'. The rationale of NaTS therapy was substantiated by elevated urinary NaSCN levels in Double Blind Clinical Trials as well as patients. Apart from cyanide, the 'cherry red' discolouration was also shown to result from binding of MIC to end-terminal valine residues of Hb, as shown by changes in 2–3DPG levels and blood gas profiles. The finding of N-carbamoylation of several other end-terminal amino acids of tissue proteins confirmed the distribution of MIC within the body, although the underlying mechanism is not yet fully understood. Possibly, the much faster S-carbamoylated compounds of the blood like glutathione and other sulphhydryl-containing enzymes like rhodanese could be responsible for re-circulation of MIC and protracted cyanide toxicity. It is hoped that eventually the enigma of the 'Bio-chemical Lesion' of MIC toxicity will be unraveled.*

By all accounts the Bhopal gas leak on the night of 2–3 December 1984, is the worst chemical disaster in history. It took a heavy toll of human lives. People started dying within hours and more than 2000 lives were lost in the first few days. Late Heeresh Chandra, the man who had to deal with it first-hand, presented the forensic aspects at the Third Indo-Pacific Congress on Legal Medicine held at Madras in December 1989, followed by Sriramachari on the histopathology and toxicological studies. According to Ivor Doney who reviewed the proceedings, 'A silent stunned audience listened with awe the terrible story of 1984, when on one tragic day poisonous fumes killed hundreds of people or maimed thousands of them in the ensuing months'. He likened this tragedy to 'Pompeii suddenly engulfed in the dust of Vesuvius, or Hiroshima when the atom bomb was dropped'. He concludes 'that the story should be told at some future international forensic meetings again and again and again'.

By 7.00 AM, 70 people were dead, by 9.00 AM 260 were dead and thereafter the figures continued to rise. Though not all dead bodies were brought to the Medico-Legal Institute (MLI), 311 bodies were received on 3.12.1984, followed by another 250 on 4.12.1984. Thereafter, the rate declined. A total of 731 bodies were received in December 1984 alone, 103 in 1985; 90 in 1986 and 44 and 22 respectively in 1987 and 1988. These figures from the morgue may not account for all the deaths in the city of Bhopal.

The MLI continued to perform autopsies on gas-affected victims in subsequent years.

## Brief clinical manifestations

According to Dureja and Saxena<sup>1</sup>, one of the earliest of the 'Rescue Teams' to reach Bhopal when panic was at its peak at major hospitals of the city, the patients could be graded symptomatically into four categories: (i) Minor eye ailments, throat irritation and cough, (ii) Severe conjunctivitis, keratitis, acute bronchitis and drowsiness, (iii) Severe pulmonary oedema leading to cardio-respiratory distress, and (iv) Convulsions, followed by cardio-respiratory arrest. Intense fatigue and muscular weakness was another common feature. Another early and comprehensive report is by Kamat *et al.*<sup>2</sup>. Soon thereafter, other clinicians like N. P. Misra<sup>3</sup>, P. S. Narayanan, and S. K. Jain had encountered similar patterns, with minor variations. Several thousands survived with a variety of morbidity and permanent disabilities. According to the recent press reports, there are a large numbers of survivors, with lingering ailments and incapacity to work.

Non-availability of any information about the toxicity of even the parent compound, MIC (methyl isocyanate), was a great impediment to institute 'detoxication measures' and lay down guidelines for therapeutic intervention and management of the victims. Hence, there was an urgent need to generate *de novo*, authentic scientific evidence and information. The ICMR rushed to the scene and tried to fill the void. It funded, amongst 24 other projects, two comprehensive studies on toxicology and a collateral pro-

S. Sriramachari is at the Institute of Pathology – ICMR, New Delhi 110 029, India.

e-mail: ssriramachari@hotmail.com

ject on PFT (pulmonary function tests)/blood gas analyses. Both these projects rapidly transformed themselves into 'multidisciplinary and multi-institutional investigations' (Tables 1 and 2).

### *Nature of the toxic gases in Bhopal*

Public attention to the high reactivity of MIC was drawn by Devkumar and Mukherjee<sup>4</sup>. It was followed by more authoritative accounts in the Varadarajan Committee Report<sup>5</sup>. According to the report, there was a massive leak of MIC stored for a long period in the incriminated Tank 610 of the Pesticide Plant of Union Carbide of India Ltd (UCIL). Several hypotheses attributed for this disaster include, 'prolonged bulk storage of 42 tons of MIC, non-functioning refrigeration system, failure of safety measures and malfunctioning of neutralization facilities'. One or more of these factors might have contributed to the accidental and uncontrolled runaway reaction. From all accounts, quite unlike leakage of a single chemical like ammonia, sulphuric acid, phosgene or hydro cyanic acid, the gas release in Bhopal is not due to mere leakage of cold MIC. The presence of an array of multiple chemicals was demonstrated<sup>5-7</sup>. Careful re-examination by the toxicology project of the ICMR, revealed the presence of as many as 21 chemical constituents, including 9 or 10 additional unidentified compounds<sup>8</sup>. However, the toxicity was NOT known about any of the compounds, including MIC.

**Table 1.** Multidisciplinary studies undertaken

Human autopsies
Histopathology
Electron microscopy
Experimental studies
Pulmonary function tests (PFT)
Elevated levels of haemoglobin (Hb)
Alterations in blood gases
Elevated 2-3 DPG (di-phospho-glycerate) levels
Evidence of acute and chronic cyanide toxicity
Therapeutic response to detoxification by NaTS
Forensic toxicology
Proof of direct binding of MIC to Hb and tissue proteins through N-carbamoylation
Faster and reversible S-carbamoylation (attempted but not successful)

While elevation of pressure and temperature inside the closed tank or container in Bhopal was widely recognized, the liberation of hydrogen cyanide (HCN) became one of the most contentious issues. In retrospect, it is amusing that the Union Carbide Corporation (UCC) decried cyanogenesis and let loose a campaign of misinformation. There were sufficient indications to that effect even in UCC's earlier reports<sup>9</sup>. And it was amply confirmed in the publication of Blake and Ijadi-Maghsoodi<sup>10</sup>, about two years prior to the Bhopal disaster. While there is no doubt about the decomposition of MIC, it was suppressed on puerile grounds, due to uncertainty of the temperature attained within Tank 610 and in the absence of consensus as to the quantity of HCN liberated at specific temperatures, say 200°C, 300°C and 420°C! Further, it was known, ever since 1927, that apart from other nitrile compounds, HCN forms an 'adduct with MIC' itself<sup>11</sup>. Depending on the reactions, theoretically it is even possible for the more lethal 'cyanogen' to be formed. It is proposed to discuss later several issues related to confirmation of 'cyanide toxicity in Bhopal'.

### **Critical human autopsy studies**

Heeresh Chandra and his colleagues started performing autopsies within 72 h of the disaster. It was noticed that the usual post-mortem lividity or cyanosis was not present; instead, there was a pinkish discolouration over all parts of the body.

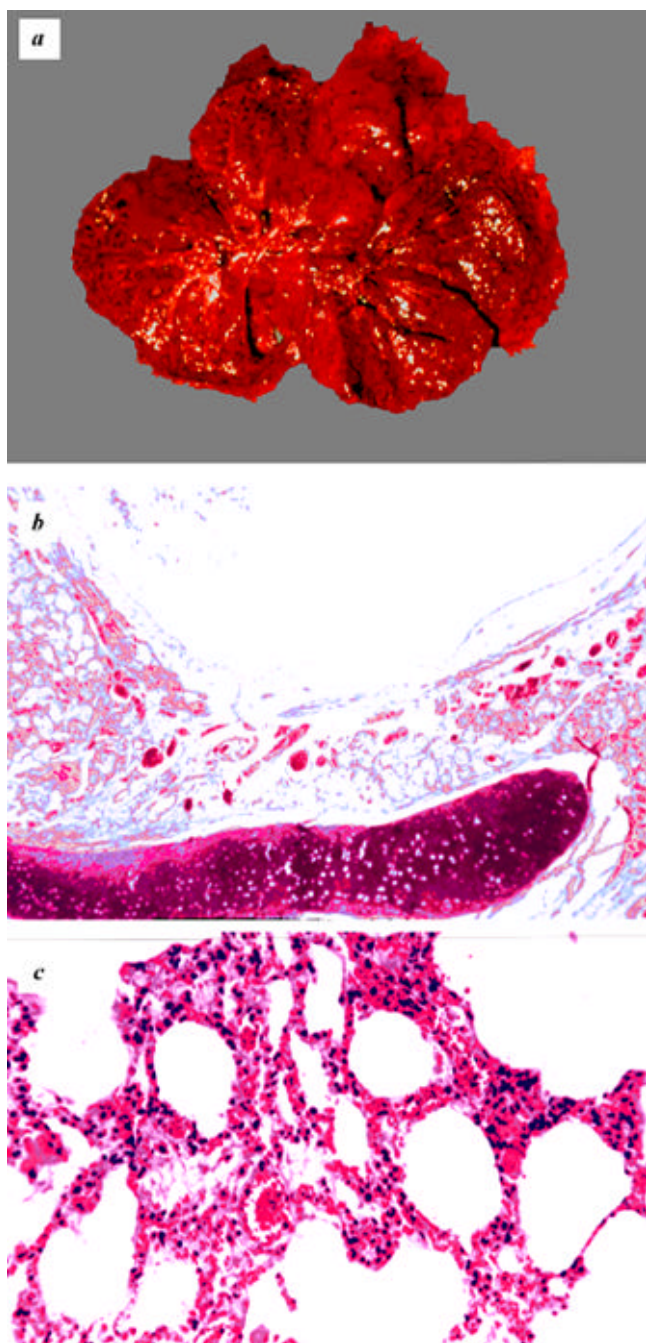
The most important findings were in the lungs. There was a gross increase in the weight of nearly 2 1/2-3 times the normal. The entire respiratory tract showed a series of pathological changes. The lungs were heavily water logged and had a distinctive cherry-red colour (Figure 1 a). The mucosa was intensely congested. The trachea and the major divisions of the bronchi revealed necrotizing or ulcerative changes. The following striking microscopic findings were noticed. Severe tracheitis and bronchitis with denudation of the epithelium was seen in some sections (Figure 1 b). There was marked congestion and thickening of the alveolar septa (Figure 1 c). The alveoli were filled with eosinophilic albuminous fluid (Figure 2 a).

**Table 2.** Trans-institutional collaboration

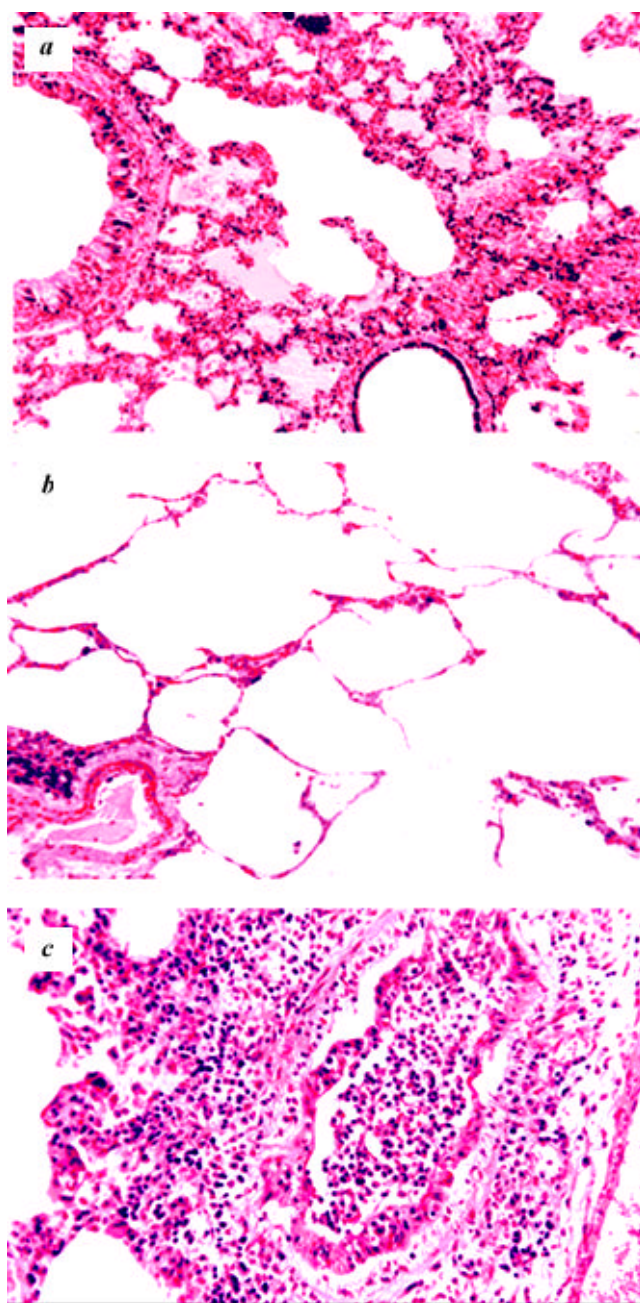
Institutions	Collaborators
Medico-Legal Institute, M.G.M. College, Bhopal	Heeresh Chandra, Satapathi, colleagues and scientific project staff
Department of Pathology, M.G.M. College, Bhopal	B. S. Darbari and S. Kanhere
Institute of Pathology-ICMR, S.J. Hospital, New Delhi	S. Sriramachari and H. M. K. Saxena, Ashok Mukherjee and A K Jain
G.B. Pant Hospital, New Delhi	P. S. Narayanan
AIIMS, New Delhi	A. Ramaiah and Roman Reddy
DRDE, Gwalior	P. K. Ramachandran and colleagues, K. Jeevaratnam
INMAS, New Delhi	N. Lakshmipathi, S. K. Sharma and Pant
DIPAS, New Delhi	K. Sridharan and A. C. Patil
IIT, Madras	D. V. Ramana
IICT, Hyderabad	M. Vairamani

Intra-alveolar hyaline membranes were seen frequently. Many sections of the lung showed extensive emphysematous areas (Figure 2 *b*). There was very little evidence of secondary infection. In some places there was necrotizing bronchiolitis (Figure 2 *c*). Polymorpho-nuclear cellular infiltrates were not very prominent. Instead, cellular response in the lung was largely one of proliferation of the alveolar macrophages.

More or less similar features were observed in a large number of autopsies carried out in the second week following the gas leak. Both grossly and microscopically, the lungs continued to be the seat of primary change. The lung parenchyma showed varying degrees of bronchiolitis, bronchopneumonic changes and infiltration of the alveolar spaces by polymorpho-nuclear cells, around and within the lumen of bronchioles (Figure 3 *a*). There was a



**Figure 1 a–c.** Early autopsy findings. *a*, Gross picture of lung shows typical cherry red discoloration; *b*, Low power photomicrograph showing marked congestion and epithelial denudation of trachea; *c*, Photomicrograph of lung parenchyma showing marked congestion and thickening of alveolar septa.



**Figure 2 a–c.** Early autopsy findings. *a*, Photomicrograph showing terminal and respiratory tubules, interstitial congestion and intra-alveolar oedema and some emphysema; *b*, Photomicrograph of sections of lung with bullous emphysema showing destruction of alveolar septa and coalescence; *c*, Photomicrograph shows peribronchial and intraluminal bronchiolitis suggestive of necrotizing bronchiolitis.

gradual transition in the pathological changes. There was persistence of acute desquamative changes in the trachea and the main divisions of the bronchi. The alveolar spaces also showed a variable degree of infiltration by inflammatory cells.

In the acute phase, the other viscera showed gross appearance of oedema of the brain and congestion of the leptomeninges. In a few cases, the liver showed mild degree of fatty change, which might be either incidental

or secondary to severe shifts in the intra and extra-cellular fluid, apparently associated with outpouring of fluid into the pulmonary parenchyma. A noteworthy feature in the earlier series of autopsies was the marked distension of the gall bladder with excess of fluid. Curiously enough, analogues increased excretion of bile and water content of excreta has been reported<sup>12</sup> in chicks fed 'cassava rich in cyanide' content.

### Continuing autopsy studies

Excluding the initial lot of 22 cases studied in 1984, the Institute of Pathology received during 1985–88, representative tissue samples from over 170 autopsies. Approximately there were 90 cases in 1985; 18 in 1986; 17 in 1987 and 47 in 1988, although there is a possibility of some overlap in the dates.

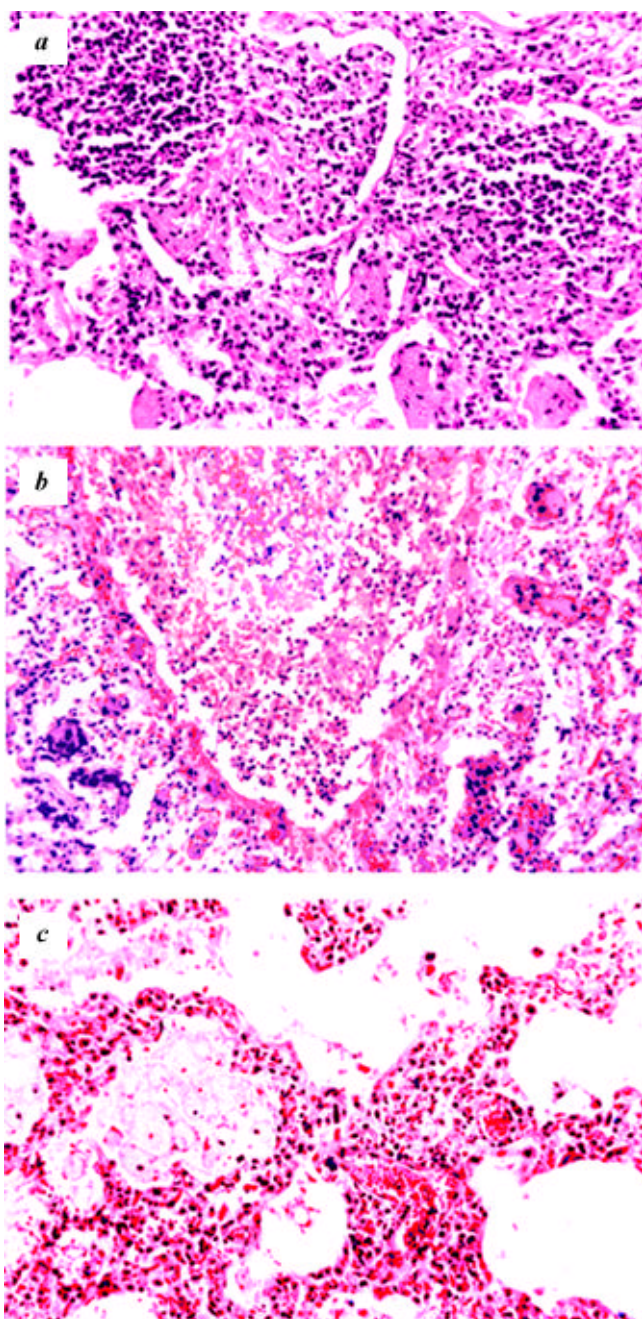
In 1985 the earlier picture of pulmonary oedema, bronchopneumonia and bronchiolitis seems to be gradually replaced by a picture of diffuse interstitial pneumonitis, but without any significant fibrosis. There was progressive decrease of oedematous fluid accompanied by well-defined interstitial mononuclear cellular reaction, histiocytosis and macrophages. At this stage, no significant changes indicative of passive venous congestion were present.

The autopsy material obtained in 1986–87 showed a picture of interstitial pneumonitis with thickening oedema and increased cellularity of the alveolar septae progressing to more organized fibrosis. Apart from the presence of 'bronchiolitis obliterans' in an occasional field (Figure 3 *b*), there was evidence of 'desquamative interstitial pneumonitis' (DIP) (Figure 3 *c*). An occasional case showed evidence of 'giant cell interstitial pneumonitis' (GIP) (Figure 4 *a*) of the usual or giant cell type. A unique autopsy case of a young doctor exposed to toxic gases on 3.12.1984 who died in the middle of 1987, revealed significant findings. Multiple sections of the lung showed broncho-pneumonic changes, superimposed with a picture of desquamative alveolitis with large collections of macrophages. (Figure 4 *b*). Normal or functional alveoli were scarcely seen in most of the sections. There was evidence of atelectasis with intervening pulmonary fibrosis. The findings were suggestive of marked interstitial fibrosis or 'fibrosing alveolitis' (Figure 4 *c*). Yet another significant observation in 1986–87 is the picture of chronic passive venous congestion of the liver with characteristic features of congestion, necrosis and pigmentary changes indicative of right heart failure.

The material received in 1988 showed a similar picture, but of a more organized nature. There was greater fibrosis of alveolar septae and patchy fibrosis of lung parenchyma.

### Histopathological changes in other organs

The brain, in general, showed in the acute phase hallmarks of gross oedema and congestion of the leptomeninges. In a few cases there was obvious evidence of sub-arachnoid

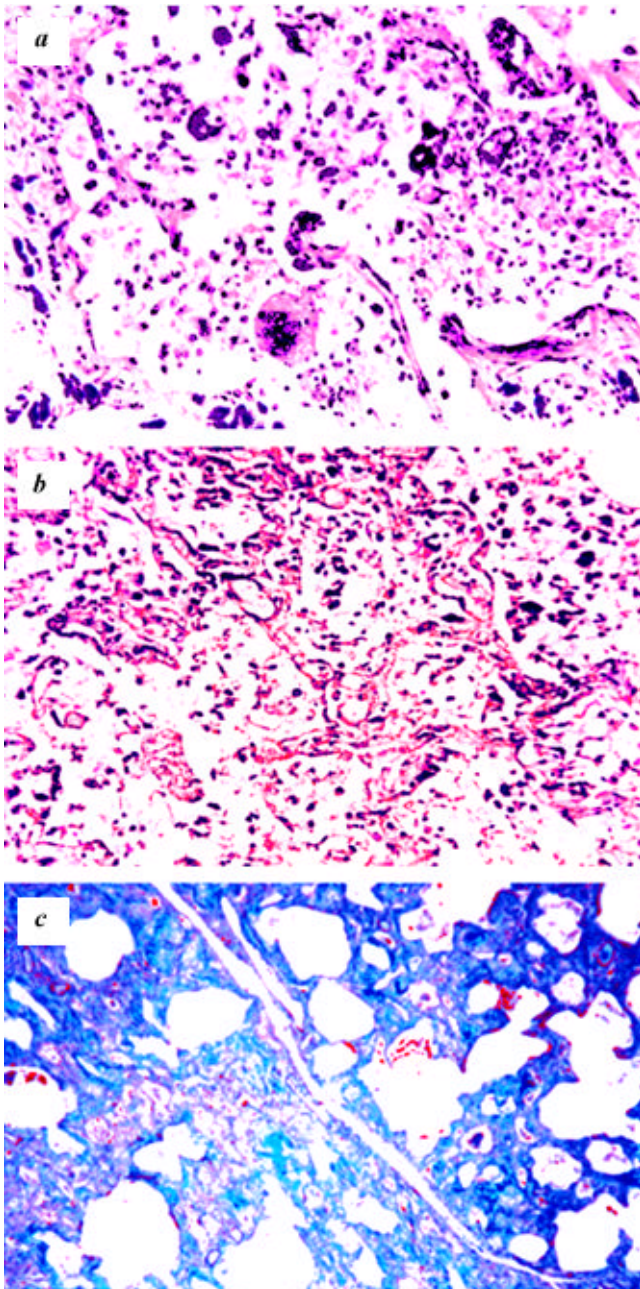


**Figure 3 a-c.** Progression of autopsy findings in the lung. *a*, Photomicrograph showing picture of early bronchopneumonic consolidation; *b*, Photomicrograph showing atypical picture of *bronchiolitis obliterans*; *c*, A later autopsy shows a picture of congestion and interstitial pneumonitis with intra-alveolar macrophages.

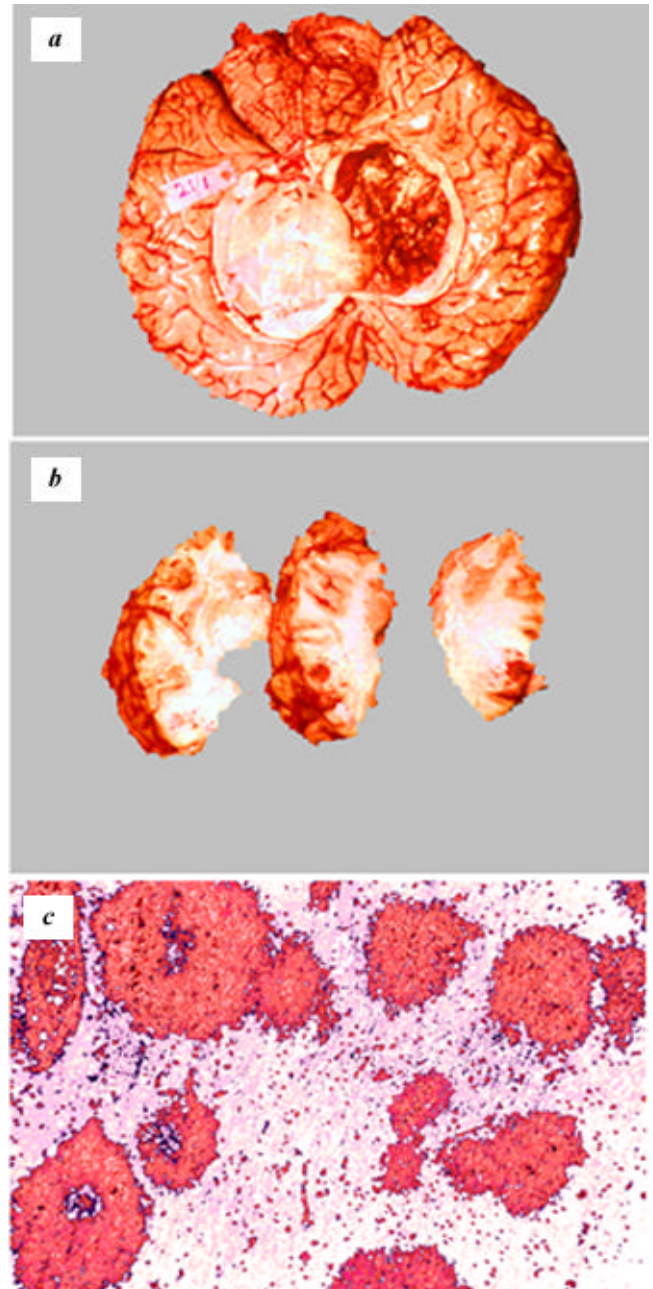
and intra-ventricular haemorrhages (Figure 5 *a*). Occasional cases also showed grossly cortical and sub-cortical ring haemorrhages (Figure 5 *b*). Microscopically distinct pericapillary and 'focal flame haemorrhages' were seen in the cortex as well as the white matter (Figure 5 *c*). The brains in general showed evidence of generalized pericellular and peri-capillary oedema. It was more apparent in the paraffin sections (Figure 6 *a*). The same was also confirmed in the celloidin sections. Focal acute nerve cell

degeneration of Nissl was seen in a scattered manner in the dentate nucleus (Figure 6 *b*). However, there was no indication of satellitosis or neuronophagia. Selective neuronal damage of Purkinje cells was seen in the cerebellar folia (Figure 6 *c*).

The liver showed a picture with normal appearance in most of the cases, with some degree of moderate fatty change in a few cases and necrosis and disorganization of the liver cell cords occasionally.



**Figure 4 a-c.** Late autopsy findings. *a*, Photomicrograph showing an occasional picture of giant cell interstitial pneumonitis; *b*, Photomicrograph showing a picture of bronchopneumonia superimposed by desquamative alveolitis; *c*, Photomicrograph of the same case showing extensive atelectasis and fibrosing alveolitis (Masson Trichrome Stain).



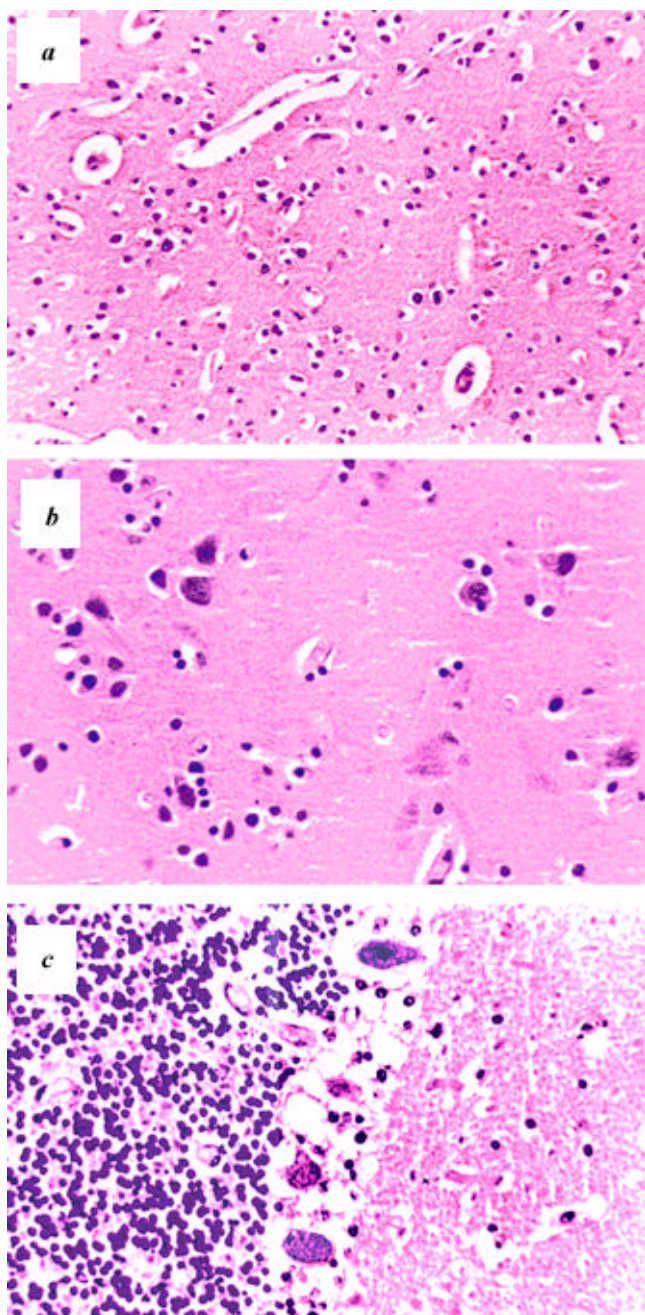
**Figure 5 a-c.** Autopsy findings in other organs. *a*, Gross appearance in early autopsy with marked sub-arachnoid congestion and intraventricular haemorrhages; *b*, Cortical and sub-cortical haemorrhages in gross sections of the brain seen occasionally; *c*, Photomicrograph of the brain showing peri-capillary flame haemorrhages.

The kidney showed in a few cases acute tubular necrosis, particularly of the proximal tubules. The medulla in such case showed congestion and presence of tubular casts in the collecting ducts.

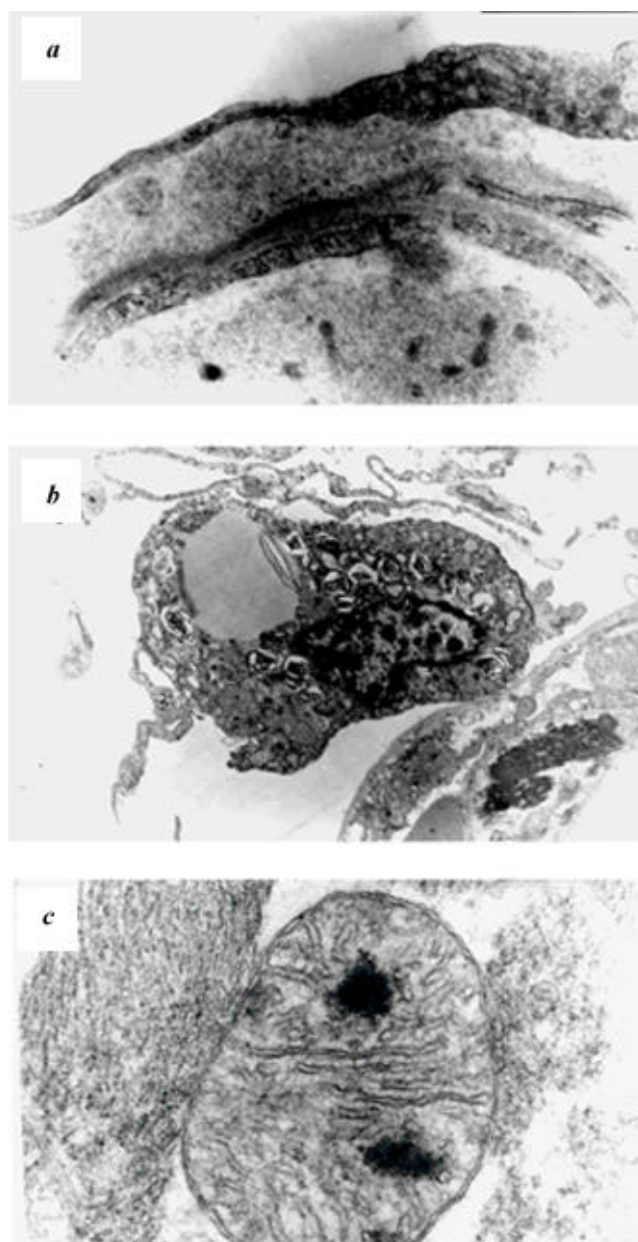
**Ultrastructural changes**

The study indicated certain interesting changes, which supported the light microscopic findings. The alveoli of

the lungs showed a consistent picture of thickening of the alveolar membrane. Although there was a marked reduction of the epithelial lining or Type-I pneumonocytes (Figure 7 a), it is significant that Type-II pneumonocytes were present in large numbers as electron-dense whorl-like material (Figure 7 b). This probably represents an attempt at enhanced synthesis of the surfactant material phosphatidyl ethanolamine. There was no evidence of acute myocardial infarction or myolysis except for the presence of oedema. Electron microscopic examination of heart muscle tissue revealed the presence of degenerated mitochondria



**Figure 6 a-c.** Autopsy findings in the brain. *a*, Photomicrograph showing peri-cellular and peri-capillary oedema suggestive of cerebral anoxia; *b*, Photomicrograph showing focal acute nerve cell degeneration of dentate nucleus of cerebellum suggestive of selective neuronal damage due to anoxia; *c*, Photomicrograph of typical anoxic changes with the partial loss of Purkinje cells of cerebellar folia.



**Figure 7 a-c.** Early ultra structural changes. *a*, Alveolar septa showing reduction of type I pneumonocytes; *b*, Electron micrograph showing increase of type II pneumonocytes with whorl-like electron dense material suggestive of increased production of surfactant; *c*, Electron micrograph of mitochondria of cardiac tissue showing floccular degeneration.

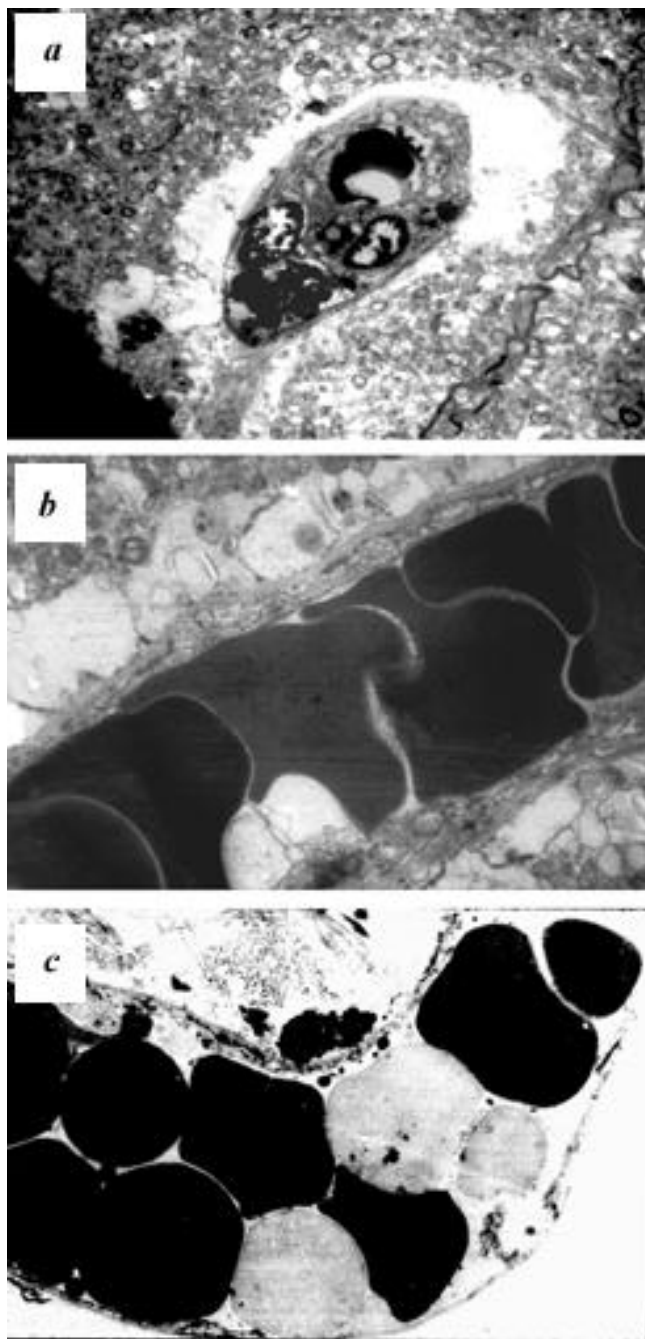
dria with floccular masses (Figure 7 *c*). However, it is to be pointed out that these ultra-structural findings were seen sparsely.

Electron microscopy of the brain tissue also confirmed the enlargement of pericapillary Virchow–Robin spaces (Figure 8 *a*) and swollen oligodendroglial cells and astro-

cytic processes abutting on the pericapillary gliovascular membranes (Figure 8 *b*). Interestingly, some of the erythrocytes within the capillaries were electron lucent (Figure 8 *c*). This is suggestive of leaching out of some lipid substances of the erythrocyte membrane, possibly due to loss of carbamoylated glutathione.

### Experimental studies

As pointed out earlier, practically nothing was known about the toxicity of MIC, except for some acute experiments conducted by UCC in the Bushy Run Laboratories. In the aftermath of the Bhopal gas leak, several experimental studies were undertaken in different parts of the world. But most of them dealt with the study of its irritant effects on repeated exposures. Only Nemery *et al.*<sup>13</sup> attempted to study the effects of single exposure, although confined only to the acute phase. Further, it was considered desirable to know about the toxic effects of not only pure MIC, but also its aqueous derivatives, methyl amine and di-methyl urea with a view to simulating the *in vivo* situation. Hence, the pathological effects of a single exposure of rats to the above three constituents were also studied. Apart from the lethal damage, the sub-lethal effects were also studied. In addition to the inhalation route with single or two LC<sub>50</sub> doses, the toxic chemicals were administered subcutaneously at one LD<sub>50</sub> dosage. Only surviving animals, sacrificed at various time intervals, extending from one day to ten weeks, were submitted to histopathology. Care was taken to discard the dead animals, with attendant autolytic changes. In all, lungs from over 240 animals were available for study. With the help of this experiment, it was possible to reproduce the full spectrum of histopathology of lung, seen in the human victims. Some of the B&W illustrations published<sup>14,15</sup> have since been reproduced as colour photomicrographs. Initially, at the end of 24 h there was an overwhelming bland oedematous fluid filling up of the alveoli and eosinophilic necrosis of the bronchial epithelium (Figure 9 *a* at one LC<sub>50</sub> and Figure 9 *b* at two LC<sub>50</sub> dosages). Even when administered subcutaneously at a dosage of one LD<sub>50</sub>, the lung was found to be the target organ with intense interstitial pneumonitis although without any noticeable oedema (Figure 9 *c*). This is in consonance with the so-called ‘special vulnerability’ with alveolar membrane by the inhalational route as shown earlier in the case of ‘phosgene’ (cited by Cohen and Oppenheimer<sup>16</sup>). At subsequent periods, the sequelae of intra-alveolar oedema and interstitial pneumonitis, and bronchitis and even fibrosis were observed by the end of one week (Figure 10 *a* and *b*) and with both the routes of administration. Even diffuse pulmonary fibrosis could be demonstrated by the end of ten weeks (Figure 10 *c*). Thereby, it has been possible to establish experimentally MIC toxicity. It is noteworthy, that methyl amine produced similar lesions, *albeit* less



**Figure 8 a–c.** Early ultra structural changes. *a*, Electron micrograph showing enlargement of Virchow–Robin pericapillary spaces indicative of extensive oedema; *b*, Electron micrograph of another area showing capillary packed with erythrocytes and oedematous changes in the gliovascular membrane in astrocytic processes and oligodendroglia; *c*, Electron micrograph of a capillary structure in the brain showing electron lucent erythrocytes suggestive of loss of some material.

severe than MIC itself. DMU caused still milder and transient changes<sup>14,15</sup>.

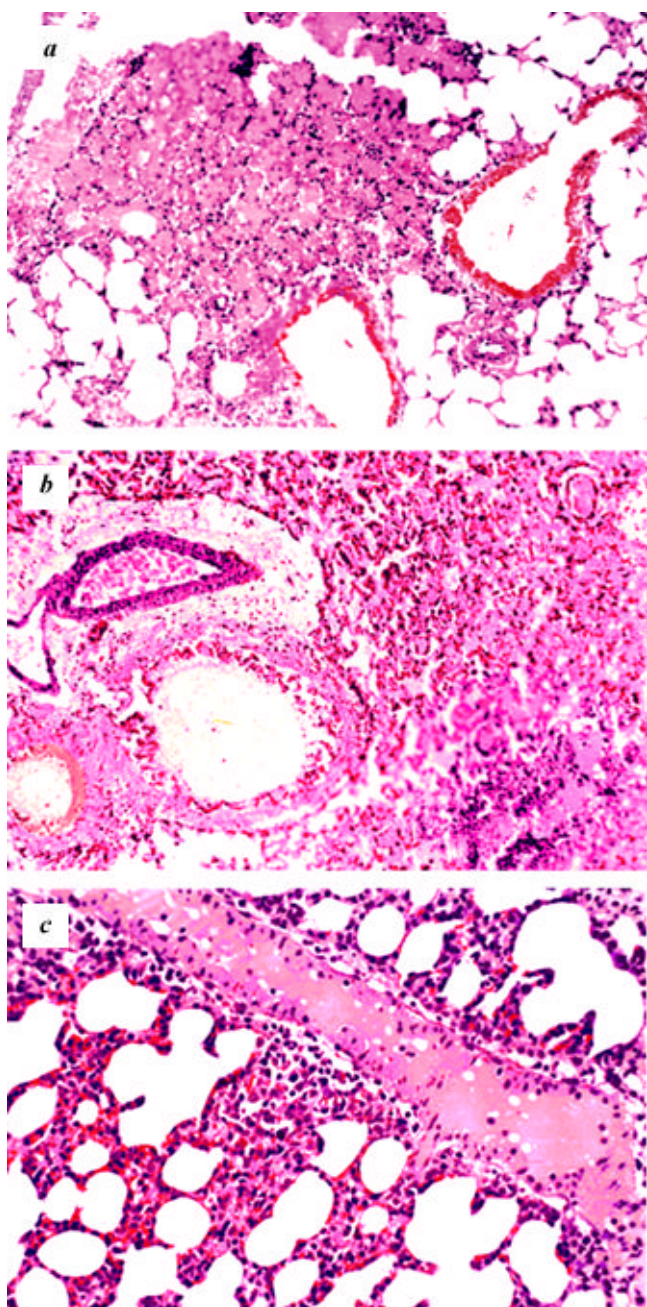
**Toxicological studies**

The main purpose of toxicological studies was detection of the possible toxic substance(s) and to determine appro-

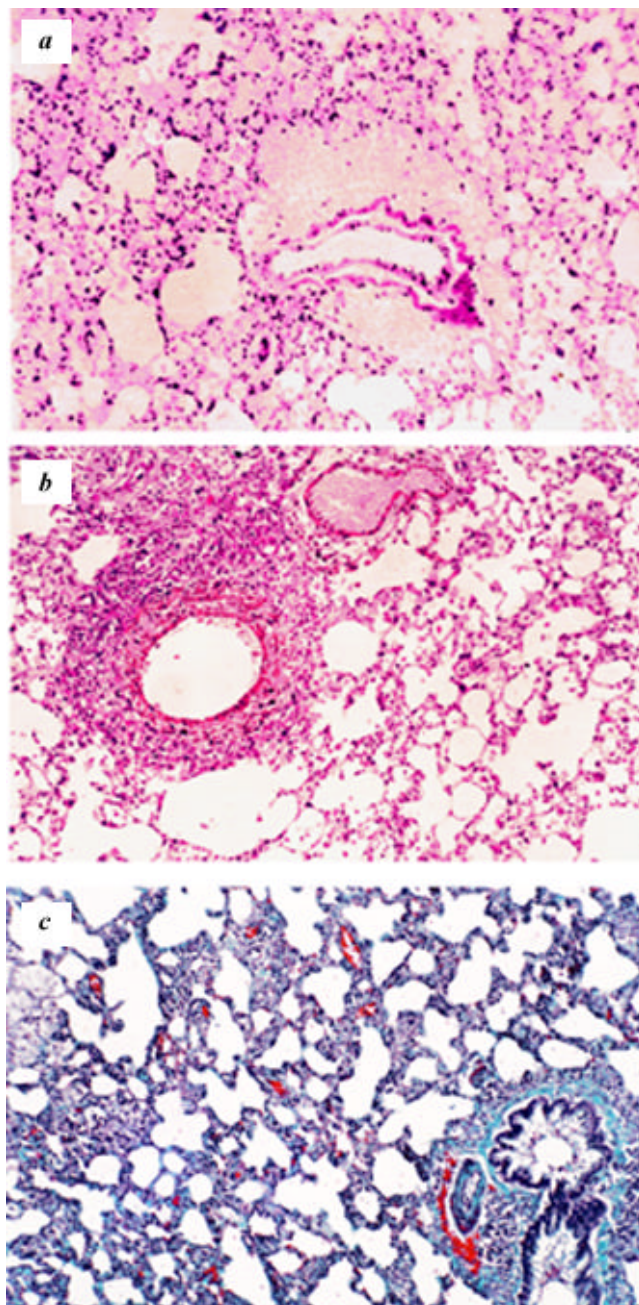
priate antidotes on an emergency basis. Thus the observation of the cherry red colour of lung and viscera assumed great importance, and even overshadowed all other factors.

*Issue of cyanide toxicity*

On the basis of autopsy findings, Heeresh Chandra postulated cyanide toxicity as a causative factor. Max Daunde-



**Figure 9 a-c.** Early stages of experimental studies in rats. *a*, 24 h picture of lung exposed to one LC<sub>50</sub> dose of MIC showing eosinophilic necrosis of bronchiolar epithelium and lobular distribution of intra alveolar oedema; *b*, Similarly exposed to two LC<sub>50</sub> doses of MIC showing more extensive pulmonary damage as in the above; *c*, Exposed to one LD<sub>50</sub> dose of MIC subcutaneously; still the lung is the target with marked interstitial pneumonitis.



**Figure 10 a-c.** Late stages of experimental studies. *a*, Photomicrograph of lung at the end of one week showing extensive pulmonary interstitial oedema; *b*, Photomicrograph at the 4 week showing a picture of mild oedema, bronchiolitis and interstitial pneumonitis; *c*, Photomicrograph at the end of 10 weeks showing a picture of diffuse pulmonary fibrosis.



rer, a German toxicologist, who came to Bhopal in the first week after the accident, also reiterated this fact. Based on his perception of possible cyanide toxicity, Daunderer brought diagnostic kits and ample supplies of the antidote, sodium thiosulphate. These developments spurred vigorous research into the possible causes of the 'cherry red' discolouration. A series of pathophysiological and toxicological studies were undertaken on an emergency basis. Certain preliminary investigations, with positive or negative results at each stage, paved the way for subsequent studies. 'Direct vision spectroscopy' and spectrophotometry of blood were initiated as early as 14.12.1984, i.e. second week after the disaster. However, none of the samples examined showed evidence of carboxy-haemoglobin or cyan-methaemoglobin. In all samples of all the victims, only the twin absorption bands characteristic of oxy-haemoglobin were seen.

### *Preliminary therapeutic trials with NaTS and enhanced urinary SCN response*

Attempts to repeat the experiments of Daunderer met with variable results. Twenty very ill patients unrelieved after six weeks of adequate conventional treatment with bronchodilators, etc. were subjected to NaTS therapy. Twelve were fully cured but with residual tachycardia. Two had no relief while six were continued on treatment. However, in view of the reported dramatic response to injections of sodium thiosulphate, Sriramachari postulated the need to routinely monitor the urinary thiocyanate levels of the survivors. On the analogy of studies on smokers, it was considered worthwhile to monitor routinely survivors and exposees for urinary thiocyanate levels (NaSCN), both before and after the administration of NaTS. Surprisingly enough, they were elevated three to four times

**Table 3.** First Double Blind Clinical Trial With NaTS. Urinary thiocyanate levels (in mg%) after injection of glucose or NaTS

Name	Resting	Post-glucose injection	% Change	Post NaTS injection	% Change
Sita	0.90	0.8	- 11	1.60	+ 100
Sakita	1.25	1.75	+ 40	2.80	+ 60
Azazuddin	1.00	1.35	+ 35	1.20	- 11
Satia Ban	0.50	0.30	- 40	3.00	+ 900
Devi Singh	1.50	0.80	- 46	1.20	+ 50
Sumet Lal	1.00	1.80	+ 80	0.80	- 55
Anna Malai	0.40	0.70	+ 75	1.60	+ 128
Rama Ji	1.40	0.60	- 57	1.40	+ 133
Prem Chand	2.00	0.60	- 70	0.70	+ 16
Zetru Nisa	1.80	0.80	- 55	1.20	+ 50
Mira Bai	0.50	1.20	+ 140	0.50	- 58
Raju Bagga	1.00	1.40	+ 40	1.60	+ 15
Kannaria	0.80	1.00	+ 20	1.70	+ 70
KS Pawara	0.80	1.00	+ 20	1.00	0
Beck Lal	0.70			3.15	+ 320
Puri	0.35			0.85	+ 157
Increase $\geq$ 50%			3		10
Total cases			14		16

Fischer's exact test:  $P = 0.031$ .

**Table 4.** Follow-up study of urinary thiocyanate

Group	n	1985-86	1986-87	t value	Significance
A. Males - Below 40 years	44	Mean 1.2354 SD $\pm$ 0.5446	Mean 0.8931 SD $\pm$ 4054	4.5197	99.9%
B. Females - Below 40 years	41	Mean 1.2178 SD $\pm$ 0.5446	Mean 0.7066 SD $\pm$ 0.3817	5.4961	99.9%
C. Males - Above 40 years	36	Mean 1.27083 SD $\pm$ 0.7574	Mean 0.82297 SD $\pm$ 0.3755	3.4645	99%
D. Females - Above 40 years	12	Mean 1.0341 SD $\pm$ 0.4508	Mean 0.7166 SD $\pm$ 0.2525	2.0631	ns
E. Previous values of more than 1 mg	88	Mean 1.4538 SD $\pm$ 0.3760	Mean 0.8364 SD $\pm$ 0.4040	11.2143	99.99%
F. Previous value of less than 1 mg	45	Mean 0.66272 SD $\pm$ 0.2174	Mean 0.7134 SD $\pm$ 0.3549	0.1929	ns

the normal. These findings supported a *prima facie* case of 'cyanide exposure'. In view of raging controversies prevailing at that time, abundant precautions were taken to ensure that the estimations were double-checked in some of the laboratories. Accordingly, the Institute of Nuclear Medicine and Allied Sciences (INMAS) was chosen. It was found that in comparison with the normals the affected population had twice or thrice-elevated levels, even after accounting for smoking habits, use of *Brassica* species of vegetables (cabbage and cauliflower). Several investigations on urinary thiocyanate were undertaken by the two toxicology projects.

### Controlled double blind clinical trials

However, pitted against divided medical opinion, it was considered desirable to carry out controlled double blind clinical trials (CDBTs). With adequate precautions and statistical appraisal, it was established that NaTS was beneficial in relieving the symptomatology of the victims and was also accompanied by elevation of NaSCN (Table 3).

This work was carried out by late Narayanan and Ramaiah, ably assisted by the local team of doctors, led by Abha Jain. The phenomenal improvement of the victims, including the relief of muscular weakness, was accompanied by further elevation of NaSCN. The CDBTs enabled a major policy decision of ICMR advocating widespread use of NaTS as a therapeutic measure.

### Follow-up studies

Regular clinical trials on large cohorts of patients, both adults and children, were carried out for one and a half years. Serial observations on a large cohort of 300 patients clearly established the beneficial role of thiosulphate in the earlier period, in different categories of patients. The results are given in Table 4.

Monitoring of the urinary thiocyanate levels became an accepted norm. The total study involving 19,122 samples of urine including 1079 controls, added further confidence to the validity of the hypothesis of 'disturbance in cyanide metabolism'. Thus, one of the primary objectives of the toxicological studies was vindicated as early as February 1985. When declining trends were confirmed from the end of 1985, the treatment was tapered off. Out of 143 gas-exposed subjects studied in December 1984, 46.15% showed thiocyanate excretion of > 1.00 mg%. In the following years 1985–87, it came down to 41.05% out of 7752 subjects in 1985, 38.67% out of 5698 subjects in 1986 and 29.9% out of 4450 individuals in 1987.

### Relapses and recurrences

However, therapeutic success of detoxification was not unqualified. A large proportion (nearly 30%) of patients

had a 'clinical relapse' with increased pulse and respiratory rates, out of proportion to the degree of pulmonary damage or pulmonary function tests. Raised urinary NaSCN levels often accompanied such episodes. The patients responded well to repeated doses of NaTS, thereby confirming that the underlying changes were not merely subjective, but supported by objective scientific evidence.

### Blood and tissue cyanide levels

There were initial hurdles in the matter of HCN estimations on blood and viscera with conventional methods. With the help of Head Space Analyser on a HPLC system, it was shown that HCN levels of the blood of victims or 'exposees', were more than double compared with living or normal autopsy samples (Table 5). Thus it was established that there was some degree of 'cyanide toxicity'.

### Studies on Hb, 2–3 DPG and blood gases

The possibility of 'cyanate' being directly responsible for the cherry red discolouration was simultaneously pursued in other directions. Patients admitted to the 30-bed J.L.N. Hospital showed 'recurrent respiratory problems', due to excessive muscle weakness. Surprisingly, their pulmonary status and functions were reasonably satisfactory. But a majority of them exhibited abnormal changes in certain parameters of the blood such as Hb levels. The residents of J.J. Colonies seem to have consistently elevated Hb, which persisted for nearly 1–1½ years (Table 6).

Many of the victims also had abnormally high 2–3 DPG levels which were more than double the normal, of 1.0  $\mu$  mole/ml, as if they had been at a high altitude of 14,000 ft, for over two–three weeks. It took nearly a year for 2–3 DPG levels to return to normal.

**Table 5.** Blood cyanide levels ( $\mu$ g%) in controls and exposees

Group		<i>n</i>	Range	Average
Control	Live	15	5–30	20
	Post-mortem	31	10–50	25
Gas exposed	Live	34	50–110	70
	Post-mortem	43	60–360	150

Even after two months of preservation, autopsy samples (one sample from each group) on re-examination revealed no deviation from initial values.

**Table 6.** Haemoglobin levels of 14 g and above in the victims

Time of examination	<i>n</i>	Percentage
February 1985	8/20	40
June 1985	17/38	44
September 1985	49/120	37.5
March 1987	45/121	23.6

In view of the abnormal levels of Hb and 2–3 DPG levels, it was considered worthwhile to investigate the ‘gas carriage and utilization mechanisms’ of the victims. Further, it was also decided to study these parameters, before and after administration of NaTS and correlate the changes with the clinical improvement and alterations in the blood gases. Blood gas studies of arterial and venous oxygen and carbon dioxide were undertaken with ABL-3 Blood Gas Analyser and Oxymeter. Out of 26 patients, 14 patients had a PaO<sub>2</sub> less than 85 mm of mercury (range 47.3 to 85.6 mm). Out of a batch of 14 untreated patients exposed to MIC, eight had PaCO<sub>2</sub> below 35 mm mercury, which is the accepted lower limit of PaCO<sub>2</sub>. Out of the four treated patients, one had PaCO<sub>2</sub> of 35.6 mm and all the rest had between 40 and 45 mm.

On the venous side, peripheral samples from the antecubital vein, only two out of the 23 patients investigated, had Hb less than 10 g%. Others ranged from 10 to 16 g%. Three out of 17 patients investigated had venous PvCO<sub>2</sub> of below 40 mm of mercury; while nine out of 14 had values above 46 mm of mercury of PvCO<sub>2</sub>, i.e. above the upper limit. It is concluded that the patients had low PaO<sub>2</sub>, low PaCO<sub>2</sub> and low PvO<sub>2</sub> values, and normal or high PvCO<sub>2</sub> values at rest, which did not increase on exercise. Also, the values in general could not be correlated on Hb basis.

Apart from clinical improvement after NaTS treatment, subjective or objective, the blood gases showed the following changes: There was no significant change in PvO<sub>2</sub> which continued to remain low, indicating that the Hb showed some alterations in the oxygen-carrying capacity. Patients treated with thiosulphate had PaO<sub>2</sub> ranging from 85 mm Hg upward and O<sub>2</sub> concentration of 96%. More importantly, there was a demonstrable increase in PvCO<sub>2</sub> at rest, which was further increased after exercise. The ‘peripheral as well as central’ catheterized venous CO<sub>2</sub> concentration was equally elevated. This increase in PvCO<sub>2</sub> *pari passu*, with definite clinical improvement, suggests the relief from ‘chronic recurrent cyanide poisoning’. Typical cases showing increase in the PvCO<sub>2</sub> values after NaTS therapy are shown in Table 7.

### Studies on carbamoylation

The issue of alterations in the oxygen-carrying capacity led to further investigations on possible carbamoylation

**Table 7.** Therapeutic reversal after sodium thiosulphate

Name	Status	PvO <sub>2</sub>	PvCO <sub>2</sub>
Azazuddin	Pre	25.4	47.3
	Post	34.0	53.5
Wahid	Pre	35.0	44.8
	Post	28.6	51.1

of the alpha and beta chains of the haemoglobin molecule. Ever since the occurrence of the Bhopal episode and the description of the cherry red discolouration of blood and lungs by Heeresh Chandra, several alternative hypotheses were entertained, even within the ICMR Toxicology Project. Towards the end of December 1984 itself, Sriramachari postulated that there could be several factors that can cause cherry red discolouration. Although the role of carbon monoxide and cyanide is well known, there are other lesser-known factors, such as aliphatic and aromatic nitriles and organic thiocyanates contributing towards the ‘cyanogen pool’. Isocyanate itself, directly by carbamoylation of the end-terminal amino acids of the alpha, and beta chains of the Hb molecule can modify the oxygen affinity of blood. This could result in ‘left shift of the Bohr effect’. Failure of deoxygenation or inability to shed oxygen due to reduction of CO<sub>2</sub>-carrying capacity could be the possible cause. The work of Cohen and Oppenheimer<sup>16</sup> supports such possibilities. These aspects were verified from January 1985 onwards.

*Reduction of free amino groups.* Reduction in the ‘free-amino groups’ of the samples of blood from Bhopal was assessed. It was soon established that there was a 20–40% reduction of ‘free amino groups’, by the tri-nitro benzene sulphonic acid, TNBS Technique (Ramaiah *et al.*, unpublished data). It was not certain whether all the reduction was due to N-carbamoylation, since its greater interaction with SH groups of glutathione etc. could not be excluded<sup>17</sup>.

*Carbamoylation of Hb.* Further investigations confirmed the presence of ‘carbamoylated end-terminal valine residues’ of the Hb molecules, both in experimental and clinical material from Bhopal<sup>18</sup>. Out of a batch of 60 samples of blood, 19 were found positive for N-carbamoylated methyl valine hydantoin (MVH)<sup>19</sup>. The scope of this work was enlarged at MLI, Bhopal, with the acquisition of HPLC and GCMS equipment<sup>20</sup>. Figure 11 shows the possible stages in the interaction of MIC with end-terminal valine residues of Hb chains. Mass spectrometric evidence of N-carbamoylated valine agreed with Finnegan Matt Spectrometer Library Reference data (Figure 12). Increasingly, a large number of cases were shown to be positive for MVH<sup>19</sup> and occasionally ‘non-methylated valine hydantoin’ (VH)<sup>21</sup>, suggesting the possibilities of break-up of MIC into HNCO, either in the atmosphere or demethylation processes in the human victims. Indeed, carbamoylation of Hb was proof of the MIC crossing the ‘alveolar-capillary barrier’ and spreading throughout the body, contrary to the initial statements of the Union Carbide from December 1984 onwards.

*Tissue carbamoylation.* Due to non-availability of proper reference standards, Heeresh Chandra and colleagues prepared a set of N-methyl carbamoylated hydantoins. First,

the five amino acids, glycine, valine, phenyl alanine, methionine and threonine were used. Later, another batch of five amino acids, viz. serine, glutamic acid, glutamine, alanine and histidine were included. Unfortunately, the results with cysteine were not satisfactory. All the hydantoins were counter-checked with mass spectrometric data available with reference library. Chloroform extracts of preserved samples of autopsy tissues from exposees as well as controls, were screened for the presence of N-carbamoylated end-terminal amino acids of tissue proteins. A summary of the studies is given in Figure 13. Perhaps in the history of chemical disasters these findings are a unique example of tracing the offending chemicals to the blood and tissues of the victims.

*Limitation of N-carbamoylation.* However, the results of N-carbamoylation did not fully answer the issues of recurrence and repeated episodes of illness in the patients. It was observed that, on the analogy of some information generated in the ITRC, there was a reduction in the glutathione content of the blood<sup>22</sup>. The ICMR Toxicology

Group felt that it could be due to transport across the tissues of the much faster and reversible S-carbamoylated glutathione.

*Possible role of S-carbamoylation.* Unfortunately, due to the lack of access to appropriate CI (Chemical Ionisation), GCMS, the problem could not be pursued further. However, Bailie and Slatter<sup>23</sup> had demonstrated experimentally that glutathione undergoes S-carbamoylation and functions as an exchange pool or a reservoir of the isocyanate in the body. For want of further evidence, perhaps it can only be surmised that reversible S-carbamoylation of acetyl choline esterase and aldolase may account for repeated episodes of muscle weakness, experienced by the Bhopal victims.

As pointed by Heinrickson<sup>24</sup>, the enzyme rhodanese can be selectively inactivated by phenyl glyoxal, combined with cyanide, at any of the two-cysteiny residues at 247, 254 and 263 positions in the 'catalytic apparatus' of its B-domain. It is possible that in the Bhopal victims S-carbamoylated rhodanese is continually and reversibly inactivated under conditions of *in vivo* build-up of endogenous cyanide in the body. In all probability, the metabolic block of the 'catalytic apparatus' is corrected by repeated exposure to 'sulphane-sulphur' of NaTS. It is hoped that the dilemma will be resolved about 'recurrent endogenous chronic cyanide toxicity' following exposure to MIC. However it must be admitted that in our studies, as of then, we failed to demonstrate S-carbamoylation.

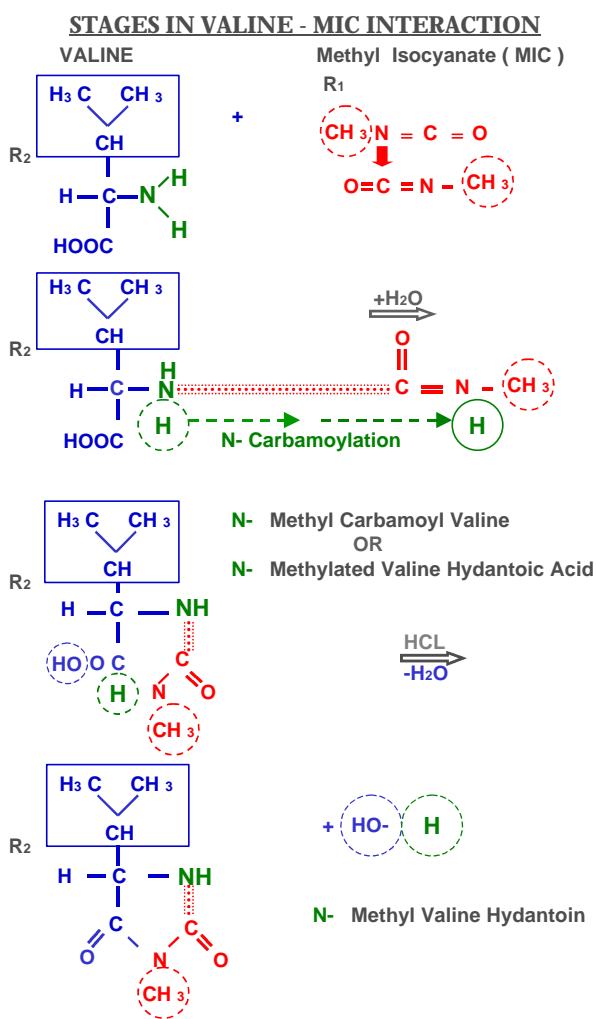


Figure 11. Chemical pathways of N-carbamoylation.

*Tank residue studies*

Attention has already been drawn to the reports on the generation of a large array of chemicals in the course of pyrolysis of MIC in Bhopal. The ICMR Toxicology programme confirmed and enlarged the findings. Mass spectrometric analysis of chloroform residue confirmed and enlarged the range of chemicals that could be detected<sup>25</sup> (Figure 14 a, b). Apart from the presence of known chemicals like MIC trimers, some of the unidentified compounds could be demonstrated in the autopsy samples of blood and tissues<sup>26,27</sup>. Although the toxic effects of such compounds remain an enigma, they are certainly of forensic evidentiary value.

**Discussion**

The moment the Bhopal gas disaster took place, the Union Carbide Company adopted a policy of *suppressio vary and suggestio falsi*. Concerted efforts were made to spread the message of disinformation. Invoking the rapid clearing of ocular changes, it was suggested that, on contact with aqueous surfaces, MIC is rapidly broken down to the relatively innocuous methyl amine and that MIC as such does not cross the alveolar-capillary barrier. No cognisance was taken about the high reactivity and chemical

binding of MIC to end-terminal amino acids of blood and tissue proteins as discussed by Cohen and Oppenheimer<sup>16</sup>.

Secondly, it was suggested that acute anoxia and pulmonary oedema are transient and they would soon be

corrected and the fluid reabsorbed. Strangely enough, ignoring the adverse effects of a highly reactive chemical, even Indian scientists echoed similar sentiments. In his Presidential oration of the January 1985 Session of




Figure 12. Comparison of mass spectrometric data of N-carbamoylation of valine residues of Hb of a victim compared with that of library reference standard.

Studies on carbamoylation

Source	1984		1985		1986		1987		1988		TOTAL
	C	E	C	E	C	E	C	E	C	E	
Postmortem Blood	nil	7 (7)	nil	9 (4)	2	5 (1)	6	8	1	8	T-46 C-09, E-37
**	-	7/7+	-	2/2+	2/0	3/1+	6/0	3/0	2/0	2/0	T-27 C-10, E-17
Clinical Blood	nil	nil	nil	3 (1)	2	3	9	13	1	2	T-33 C-12, E-21
Postmortem Tissues	nil	35 (17)	1	18 (4)	nil	14	16	41	12	54	T-191 C-29, E-162
**	-	13/7+	1/0	6/2+	2/0	2/0	3/0	2/0	2/0	1/0	T-31 C-08, E-23

In parenthesis are the number of samples showing chromatographic evidence of carbamoylation with reference to five amino acids; \*\*Samples confirmed on GC-ITD; T, Total; C, Control; E, Exposed.

Figure 13. Summary table of N-carbamoylation of clinical and autopsy samples of blood and tissues.

the Indian Science Congress, Paintal<sup>28</sup> suggested that the oedema would disappear by itself, on the analogy of High Altitude Pulmonary Oedema (HAPO).

Thirdly, the issue of 'cyanide toxicity' was hotly contested<sup>29</sup>. The Union Carbide mobilized international scientific opinion to belittle the ongoing toxicological studies in the wake of the Bhopal disaster (Ballantyne 1995, pers. commun.). The rapid binding or adduct formation of HCN with MIC was ignored or missed by both Indian and foreign media and the scientific community. It is indeed a

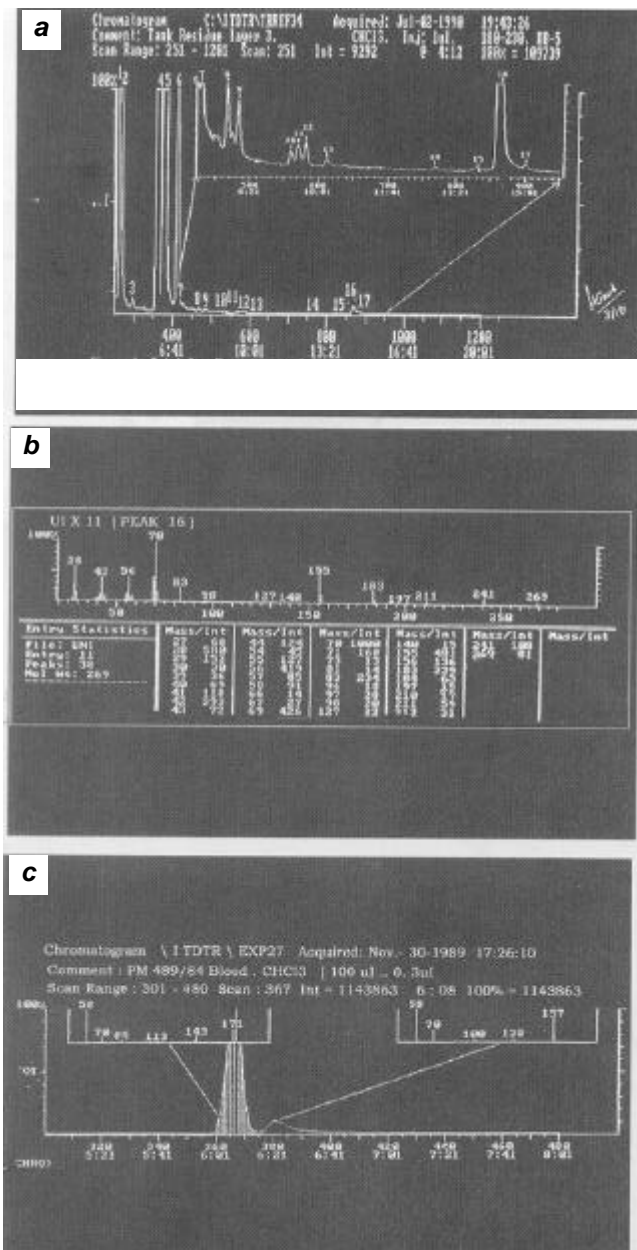
matter of satisfaction that in the teeth of opposition, the toxicology projects by ICMR were able to generate viable evidence on some of these issues.

In the projects relating to toxicology, an attempt was made to describe the series of pathological and biochemical alterations. These studies were by no means exhaustive. In fact there are a few other studies which dealt with different aspects of clinical and laboratory studies, including immunological and chromosomal aspects<sup>30</sup>. However, it is not clear to what extent some of them are incidental changes unrelated to the pathogenesis of the lesions. Therefore in our studies an attempt was made to interpret the significance of the changes, which have a bearing on the patho-physiology or toxicity of MIC or its breakdown products.

As stated earlier, the Bhopal disaster cannot be attributed to exposure to a single chemical like MIC, at normal temperature. Instead, it is the combined effect of 'cold MIC' super-added with its pyrolytic products, following the powerful exothermic reaction in a closed stainless container or tank. Indeed, the complex and variegated clinical manifestations can be explained by correlating the adverse effects of several compounds (MIC, etc.). MIC toxicity in human beings in Bhopal can be broadly classified into two categories, viz. MIC itself and 'products of its pyrolysis'. It is impossible to distinguish the overlapping time sequences of each one of the components and in terms of any logical sequence of events. Within these limitations an attempt was made to interpret the findings.

*Effects of pyrolysed MIC*

Products of pyrolysed MIC, like carbon monoxide, ammonia and HCN could result in formation carboxy-haemoglobin, methaemoglobin and cyan-methaemoglobin. Theoretically, the last two can contribute towards the cherry red discolouration of blood and viscera. However, in the light of the negative spectroscopic findings, they do not seem to be present in significant amounts. But the permanent cherry red colour could be the result of damage of cytochrome oxidase system and damage to the respiratory centres, causing instantaneous death of many victims. The subsequent alterations in the blood gases such as fairly high PaO<sub>2</sub> but low PaCO<sub>2</sub> and high PvO<sub>2</sub> and low PvCO<sub>2</sub> resulting in cherry red colour, are strongly suggestive of 'acute cyanide toxicity'. Increased plasma and urinary thiocyanate and prompt response to NaTS gave further credence to acute cyanide toxicity. These findings were initially challenged as speculative. The elevated levels of blood and tissue cyanide in the Bhopal exposees provided further confirmatory evidence. Bhattacharya *et al.*<sup>31</sup> demonstrated that MIC pyrolysed at high temperatures caused inhibition of 'cytochrome oxidase activity' of brain tissues.



**Figure 14 a-c.** Mass spectrometric analysis. *a*, Total ion chromatogram of chloroform-extract of the residue from MIC-Tank E-610; *b*, Chromatogram and mass spectrum of unidentified compound, U.I. x 11, Corresponding to Peak-16 of the above; *c*, Ion chromatogram with MS analysis of two unidentified compounds detected in the blood sample from PM 489/84.

However, the subsequent features of reversibility and recurrence do not support the cyanide hypothesis. Also, the elevated Hb and 2-3 DPG levels need to be explained, apart from the cyanide issue.

### *Direct effects of MIC*

The sudden physiological changes, following the exothermic reaction of MIC on the cellular and vascular components, can be attributed only to MIC. The flooding of the respiratory tract and 'massive pulmonary oedema' are perhaps responsible for acute anoxic anoxia, rapid stimulation of the 'respiratory centres', cerebral oedema and subarachnoid haemorrhage and eventual death. While these features by themselves, cannot explain the cherry red colour, the changes in blood gases, such as lowered PO<sub>2</sub>, lowered arterial and venous O<sub>2</sub> and CO<sub>2</sub> levels can readily explain the increase in 2-3 DPG levels and increase of Hb levels and 'compensatory erythropoiesis'. The experimental study following a single exposure to MIC, MA or DMU, also confirms the sequence of transudative and exudative changes demonstrated in the experimental studies closely simulating the human autopsy findings.

The available information about the high reactivity and binding of MIC end-terminal amino acids of blood and tissue proteins was virtually ignored. However, the uniqueness of MIC toxicity became apparent with the rapid development of chemical binding of MIC to end-terminal amino and SH groups. The successful demonstration of N-carbamoylation of blood within the first 120 day life-cycle, clearly provided an alternate explanation for the cherry red discolouration, elevation of Hb and 2-3 DPG levels as well as the characteristic alterations in the blood gases, especially the lowering of PvCO<sub>2</sub> values. The subsequent restoration of the latter, both in the peripheral and central venous pool, provides an explanation for the dynamic changes in the blood gases. However, the clinical phenomenon of recurrence and reversibility by NaTS provided a clue to the much faster S-carbamoylation, rather than recurrent exposure to cyanide. In all probability, this is due to rapid reversible S-carbamoylation of sulphhydryl groups of key enzymes like rhodanese, esterase, etc. None of these features could be explained by mere accumulation of cyanide. It would appear that S-carbamoylation is probably responsible for the secondary chronic cyanide toxicity due to accumulation of endogenous metabolic products. It would appear that S-carbamoylation effects a 'labile' circulating component like glutathione and 'fixed' sulphhydryl-specific functional enzymes. It is only when the reservoirs of S-carbamoylated MIC are exhausted, the secondary cyanide toxicity in general, and MIC toxicity in particular, is corrected. These mechanisms seem to be accelerated by periodic exposure to 'sulphane sulphur' in the form of NaTS. The effects of exposure to pyrolysed MIC in Bhopal appear to be a scientific challenge, which needs further elucidation.

### Conclusions

The two ICMR projects on histopathology and toxicology have more than fulfilled the initial hopes and expectations. The sequence of pathological changes in the acute, sub-acute and chronic stages have been clearly delineated. Structurally, continuing respiratory impairment in a proportion of cases resulted in progressive pulmonary damage, including desquamative pneumonitis or fibrosing alveolitis or its variants, like DIPF and GIPF. Experimental studies with MIC and its aqueous derivatives have confirmed the pathogenesis and pulmonary changes after 'single exposure' are comparable to human autopsy findings.

The possibility cannot be excluded, at least initially, that some degree of 'exogenous HCN', due to thermal decomposition of MIC might have contributed to some degree of 'acute cyanide toxicity' and irreversible damage to cardio-respiratory and medullary centres of the victims. Perhaps in the survivors, the 'threshold limit values' were not reached, and thereby death was avoided. However, there was no escape from severe pulmonary oedema and extreme muscular weakness.

The 'cherry red discolouration' could be the immediate effect of HCN. In the long run, it would appear that N-carbamoylation, which persists through the 120-day life cycle of erythrocytes, accounted for a greater part of the phenomenon. In Bhopal the question of repeated exposure to HCN is extremely unlikely, but 'endogenous liberation of cyanide' due to partial impairment of rhodanese and S-transferases seems plausible. This may account for the raised or elevated respiratory pulse rates and muscle weakness and protracted excretion of urinary thiocyanate.

While N-carbamoylation cannot be undone, it would appear that sulphhydryl radicals contained in acetyl-choline esterase (ACE), aldolase and especially rhodanese are periodically reactivated and 'chronic cyanide metabolism' corrected. Normalcy is attained only when the MIC stored in the body is fully depleted. But, in the exigencies of an alarming human disaster, it has not been possible to try other potent sulphane donors described by Cohen and Oppenheimer<sup>16</sup>. It seems that the 'Biochemical Lesion' of Bhopal disaster may lie between the interplay of N- and S-carbamoylation.

1. Dureja, G. P. and Saxena, R. S., *The methyl isocyanate (MIC) gas tragedy in Bhopal (India)*. *Indian J. Anaesth.*, 1987, **35**, 264-268.
2. Kamat, S. R. *et al.*, Early observations of pulmonary changes and clinical morbidity due to isocyanate gas leak at Bhopal. *Postgrad. Med.*, 1985, **31**, 63-72.
3. Misra, N. P. *et al.*, Clinical profile of gas leak victims in acute phase after Bhopal episode. *Indian J. Med. Res. (Suppl.)*, 1987, **86** 11-19.
4. Devkumar, C. and Mukerjee, S. K., Methyl isocyanate: Profile of a killer gas. *Science Today*, January 1985, 10, 11 and 16.
5. Varadarajan, S. *et al.*, Report of Scientific studies on the factors related to Bhopal Toxic gas Leakage, December 1985.
6. UCC (Union Carbide Corporation), Danbury, Connecticut. Bhopal Methyl Isocyanate incident investigation team report, March 1985.

7. D'Silva, T. D. J., Lopes Anibal, Jones, R. L., Singhawangcha, S. and John, K. C., Studies of methyl isocyanate chemistry in the Bhopal incident. *J. Org. Chem.*, 1986, **51**, 3781–3788.
8. Rao, G. J. *et al.*, Bhopal gas disaster: Unidentified compounds in the residue of the MIC Tank-610. *J. Indian Acad. For. Sci.*, 1991, **30**, 13–18.
9. *Reactive and Hazardous Chemicals Manual*, UCC (Union Carbide Corporation), 1967.
10. Blake, P. G. and Ijadi-Maghsoodi, S., Kinetics and mechanism of the thermal decomposition of methyl isocyanate. *Int. J. Chem. Kinet.*, 1982, **14**, 945–952.
11. Slotta, K. H. and Tshesche, R., *Berichte*, 1927, **60**, 1021 cited by Blake and Maghsoodi.
12. Panigrahi, S., A review of the potential for using cassava root meal in poultry diets. In *Tropical Tuber Crops* (eds G. T. Kurup *et al.*), Oxford and IBH, New Delhi, 1996, pp. 416–428.
13. Nemery, B., Dinsdaale, D., Sparrow, S. and Ray, D. E., Effects of methyl isocyanate on the respiratory tract of rats. *Br. J. Ind. Med.*, 1985, **42**, 799–805.
14. Jeevaratnam, K. and Sriramachari, S., Comparative toxicity of methyl isocyanate and its hydrolytic derivatives in rat: I pulmonary histopathology in the acute phase. *Arch. Toxicol.*, 1994, **781**, 1–6.
15. Sriramachari, S. and Jeevaratnam, K., Comparative toxicity of methylocyanate and its hydrolytic derivatives in rats: I-Pulmonary histopathology in the subacute and chronic phase. *Arch. Toxicol.*, 1994, **787**, 1–7.
16. Cohen, S. and Oppenheimer, E., *Biological Formation and Reactions of Cyanates; The Chemistry of Cyanates and their Thio Derivatives* (ed. Patai S.), John Wiley, New York, 1977, Part 2, Ch. 20, pp. 923–967.
17. Torchinsky, Yu. M., Properties of -SH groups, sulfhydryl reagents. In *Sulfur in Proteins*. Pergamon Press, Oxford, 1991.
18. Ramachandran, P. K. *et al.*, Gas chromatograph studies of the carbamylation of haemoglobin by methyl isocyanate in rats and rabbits. *J. Chromatogr.*, 1988, **426**, 239–247.
19. Sriramachari, S., Rao, G. J., Sharma, V. K., Jadhav, R. K., Saraf, A. K. and Chandra, H., GC-NPD and GC-MS analysis of preserved tissue of Bhopal gas disaster: Evidence of methyl carbamylation in post-mortem blood. *Med. Sci. Law*, 1991, **31**, 289–293.
20. Sharma, V. K., Rao, G. J., Jadhav, R. K., Chandra, H. and Sriramachari, S., High performance liquid chromatographic estimation of carbamoylated amino acids. *Curr. Sci.*, 1990, **59**, 528–529.
21. Sharma, V. K., Rao, G. J., Jadhav, R. K., Saraf, A. K., Chandra, H. and Sriramachari, S., Demonstration of methyl valine hydantoin (MVH) and valine hydantoin (HV) in blood samples in Bhopal. Proceedings of 14th Meeting of International Association of Forensic Sciences (IAFS), Tokyo, 1996.
22. Srivastava, R. C. *et al.*, Effect of exposure to toxic gas on the population of Bhopal: Part III – Assessment of toxic manifestations in humans – Haematological and biochemical studies. *Indian J. Exp. Biol.*, 1988, **26**, 165–172.
23. Bailie, T. A. and Slatter, G., Glutathione: A vehicle for the transport of chemically reactive metabolite *in vivo*. *Acc. Chem. Res.*, 1991, **24**, 264–270.
24. Heinrickson, R. L., Structure–function relationship in hepatic rhodanases, In *Frontiers in Bio-chemical and Biophysical Studies of Proteins and Membranes* (eds Liu *et al.*), Elsevier, 1983, pp. 163–192.
25. Chandra, H., Rao, G. J., Saraf, A. K., Sharma, V. K., Jadhav, R. K. and Sriramachari, S., GC-MS identification of MIC trimer: A constituent of tank residue in preserved autopsy blood of Bhopal gas victims. *Med. Sci. Law*, 1991, **31**, 194–198.
26. Saraf, A. K., Rao, G. J. and Chandra, H., GC-MS evidence of dimethyl isocyanurate and 2,4 dione of methyl isocyanate in the viscera of Bhopal victims. *Curr. Sci.*, 1995, **68**, 500–501.
27. Chandra, H., Saraf, A. K., Jadhav, R. K., Rao, G. J., Sharma V. K., Sriramachari, S. and Vairamani, M., Isolation of an unknown compound, from both blood of Bhopal aerosol disaster victims and residue of Tank E-610 of Union Carbide India Limited-chemical characterization of the structure. *Med. Sci. Law*, 1994, **34**, 106–110.
28. Lepkowski, W., Methyl isocyanate: Debate persists over mechanism of its toxicity. *Chem. Engl. News*, 1986, pp. 17–20.
29. Paintal, A. S., 'High altitude studies: Mountain preservation and prosperity' Presidential Address, 72nd Indian Science Congress, Lucknow, 1985.
30. Deo, M. G. *et al.*, Immunological, mutagenic and genotoxic investigations in gas exposed population of Bhopal. *Indian J. Med. Res. (Suppl.)*, 1987, **86**, 63–76.
31. Bhattacharya, B. K., Malhotra, R. C. and Chattopadhyay, D. P., Inhibition of rat brain cytochrome oxidase activity by pyrolysed products of methyl isocyanate. *Toxicol. Lett.*, 1987, **3**, 131–134.

ACKNOWLEDGEMENTS. This article is dedicated to the memory of the several thousands of people who perished in the aftermath of the Bhopal gas disaster and the survivors who continue to remain crippled for the remaining part of their lives. My special tribute to the following departed souls who had contributed largely to our joint research endeavours in Bhopal: Prof. P. S. Narayanan, Prof. Heeresh Chandra, Dr M. P. Dwivedi, Dr C. R. Ramachandran, Prof. V. Ramalingaswami and Dr C. R. Krishnamurthi.

Starting my research career as a 'Lady Tata Memorial Scholar' 50 years ago, I deem it as fortuitous to be associated with the symposium in honour of Sir Dorabji Tata at the Centre for Tropical Diseases. I thank Raghunath who has given me an opportunity to present a comprehensive scientific re-appraisal of the Environmental Disaster of Bhopal, long after the dust and din have settled down. My special thanks are due to Shri Pushp Raj, Ms Seema and Dr A. K. Jain of IOP for rendering all possible help in my attempts at restoration of the colour and clarity of the old illustrations.

More than a score of individual scientists had participated in the multi-disciplinary and multi-institutional ICMR projects on toxicological studies in Bhopal. Special thanks are due to Prof. N. K. Ganguly, Dr S. Varadarajan and Dr V. S. Arunachalam, for all help from the several establishments of DRDO.

Received 10 December 2003; accepted 6 February 2004